

Phenotypic Characterization of Isolation and Identification of Tinea Pedis in Athletes' Foot

Alaa Khudur Boulos, Abdulameer Jasim, Omar Sadik Shalal*

College of the Health and Medical Techniques-Baghdad, Middle Technical University, Baghdad, Iraq.

Article Info

Article history:

Received October, 01, 2024
Revised November, 15, 2024
Accepted December, 23, 2024

Keywords:

Tinea Pedis,
Athlete's Foot,
Dermatophyte,
Fungal Infection,
Biochemical Test

ABSTRACT

Tinea pedis, or athlete's foot, is a fungal infection invading the region between the toes. Although a prevalent ailment, there might be an absence of information about its transmission, risk factors, and healthcare choices among the general public.

The research included 35 male athlete participants in Iraq. The questionnaire was delivered to athletes from sports centers and clubs, which ran from December 2023 to July 2024. Skin scrapings were microscopically analysed in a 20% potassium hydroxide (KOH) mount. The dermatophyte test medium and Sabouraud dextrose agar were used for culture. Lactophenol cotton blue staining and other unique methods, such as biochemical testing like the urease and other tests, were used to differentiate macroscopic and microscopic results.

The current study aimed to find the Phenotypic Characterization of some dermatophytes in athletes' feet.

A total of 36 cases of the athlete diagnosis reported that the KOH and SDA are 100% while when using selective media such as DTM is 80 % on the other hand using a biochemical test such as Keratinase, Nitrate, Urease, DNase are 80% while lipids and carbohydrate is 70% that reveal differentiation on the phenotypic characteristic according to different species of dermatophyte infection agents.

The conventional diagnosis method seems insufficient in the presence of aberrant morphology or pleomorphism. however, our labs must use molecular approaches to identify and provide better treatment.

*Corresponding Author:

*Omar Sadik Shalal
College of the Health and Medical Techniques-Baghdad, Middle Technical University, Baghdad, Iraq.
omar.sadik@mtu.edu.iq

1- INTRODUCTION

Tinea pedis, also known as athlete's foot, happens when dermatophytes attack the skin on the foot and also Tinea refers to a fungi disease, whereas pedis is a Latin term for foot infections [1]. It is transmitted largely by direct contact with the microorganism, as typically occurs when walking barefoot. Symptoms usually appear in the interdigital areas of the toes, but may also affect the soles and margins of the foot [2]. Tinea Pedis affects at least 10% of the globe's population. Occlusive shoes were fashionable in the late 19th and early 20th centuries, leading to the prevalence of these disorders. Tinea pedis is more common in males than in females, and it seldom affects children [3] and the risk factors may include age, sex, environment (high temperature and humidity), footwear,

activity, use of public facilities, household infections, and a history of specific conditions such as obesity, diabetes, vascular problems, and bone and joint ailments [4]. Tinea pedis symptoms involve itching, scaling, and burning skin, which may lead to cracking and blisters. Tinea pedis develop in damp conditions, especially in pools and public showers [5, 6]. The skin infection is primarily caused by dermatophytes, such as *Trichophyton interdigital* and *Trichophyton rubrum* with varied clinical presentations such as interdigital, hyperkeratotic, and vesiculobullous forms [7, 8].

To prevent this condition, keep your feet clean and dry, wear sandals when possible, and avoid wearing closed-toe shoes or stockings [9]. However, Conventional methods for diagnosing tinea pedis in the laboratory involve direct microscopic examination of clinical samples to detect hyphae or arthroconidia, followed by observing the gross morphological characteristics of their colonies, such as growth rate, colony topography, surface and reverse side pigmentation. Microscopic morphology, including the shape and size of macroconidia, microconidia, and hyphae, as well as physiological criteria, are also examined. However, identifying tinea pedis can be challenging due to their similar morphological traits, variability, and pleomorphism [10]. Seeking Immediate medical assistance is crucial to prevent the spread of illness. Untreated tinea pedis can lead to serious issues and affect a person's appearance. Individuals with diabetes mellitus are at a higher risk of developing tinea pedis [11, 12].

Tinea pedis is most safely treated with topical antifungals. However, recurrent illness is common, leading to long-term therapy in many individuals [13]. Research by Song and Li found that 15.8% of tinea pedis patients were unaware of the ailment before infection. Dogan et al. found that public knowledge of tinea pedis is poor, despite its high incidence [14]. Tinea pedis, a common dermatophyte-induced infection of the skin, affects a significant portion of the global population, estimated to range between 3% to 43% in different countries [8, 15]. and Regardless of this incidence, research in Iraq shows that the population has an average comprehension and awareness of these kinds of fungal illnesses, without a significant association established among demographic features and awareness level [16]. This highlights the urgent requirement during a comprehensive public education campaign in Iraq to fill the knowledge gap in understanding concerning tinea pedis, emphasizing the significance of understanding, avoiding, and managing this prevalent disease to enhance the health of the population and decrease the economic burden from fungal diseases in the country [7].

2- MATERIAL AND METHOD

2.1 Athletes and Samples Isolation:

Sampling quality has a significant impact on mycological testing results. Match the sampling to the lesions' location by using sterile equipment to collect skin, in sterile containers. For multiple lesions, collect specimens from each location separately. Collect a suitable sample from the infected area's edge, which is the active zone of the lesion where the fungus is still present. Nails should be tested at the boundary between healthy and afflicted sections. To ensure appropriate sampling, gather enough material for microscopic inspection and culture on two media. Before sampling, some publications suggest washing the lesion site with alcohol to eliminate pollutants such as bacteria and the saprophytic fungus conidia [17].

In this study, Samples were collected from 36 male athletes who suffered from foot illness and had clinical symptoms in many clubs and sports centre Specialists in the Ministry of Youth and Sport, Al-Zwaraa Club, Air Force Club, and Army Club. The skin specimens were isolated by scraping the active margin of the web space between the fourth and fifth toes is frequently impacted, especially on the lateral toes and sole with a scalpel blade after cleaning the surface with 70% isopropyl alcohol and ensuring that it was completely dry. The samples were properly labelled and collected aseptically into a sterile container before ensuring without use of antifungal medications. between October 12, 2023, and February 28, 2024). Middle Technical University/College of Health and Medical Techniques/Department of Medical Laboratory Techniques signed agreements to do this project. All samples were sent to the Clinical Mycology Laboratory for diagnosis using the study protocol as the following.

2.2. Study Protocol:

2.3 Conventional Identification:

2.3.1. Direct Microscopic Examination With 20% KOH:

After the disinfection process, scrape the skin of the affected region with a sterile scalpel blade No. 23 and collect it on white filter paper. Mounted clinical samples with 20% potassium hydroxide (KOH) are a typical and cost-effective approach to quickly detecting fungal components within the skin, hair, and nails, notably in tinea pedis [18]. KOH microscopy is regarded as the gold standard for identifying superficial fungal infections, particularly tinea infections since it is simple, quick, and inexpensive [19].

2.3.2. Plate-Based Method:

Isolating and identifying the causative agents of dermatophytes from cultured clinical samples has been regarded as the "gold standard" for diagnosing tinea pedis [20].

2.3.2.1. Sabouraud Dextrose Agar (SDA) Medium:

Dermatophyte cultivation is the primary technique used to identify the organism and determine its viability. In the laboratory, sabouraud dextrose agar with or without cycloheximide (to promote dermatophyte development) is used to cultivate non-dermatophyte moulds (NDMs). Chloramphenicol and gentamicin may be added to the agar to prevent bacterial contamination. The culture is maintained at 25–30 °C for up to a month [21].

2.3.2.2. Dermatophyte Test Medium (DTM):

The medium supports dermatophyte growth, resulting in a colour shift from yellow to red within 14 days. The study aimed to analyze the visible features of both the front and rear colonies and investigate any diffuse pigmentation on the Dermatophytes test medium. Dermatophytes colonies have a variety of textures, including cottony, powdery, and suede-like, as well as different colours, sizes, and various morphologies. The DTM incorporates a pH indicator (phenol red), which alters the colour of the medium. Dermatophytes create alkaline metabolites, causing the medium to become pink at pH >8.2. At pH ≤ 6.8, it is yellow [22].

2.3.2.3. Subculturing And Purification of Fungal Isolates:

To create pure cultures, subcultures were made by transferring hyphal tips from the colony edge onto new SDA plates using flame-sterilized blades. The plates were then incubated at 27°C to achieve pure cultures. To prevent contamination, the Petri plates containing pure cultures of the test fungus were sealed with paraffin. These pure cultures were then utilized to identify fungal isolates using a compound microscope and guides [23].

2.4. Biochemical Tests:

In this study Biochemical tests, such as the urease test, etc. were performed to detect dermatophytes in the athletes' feet.

2.4.1 Urease Test:

The test tube that contained Christensen's urea agar was used to determine the urease production of the collected dermatophyte species. The slant surface of the medium was infected with a pure culture of the test fungus and cultured at room temperature (27 °C) for seven days. A colour change from (straw to pink) in the media signified a positive test result, whereas no colour change was interpreted as a negative [24].

2.4.2. Nitrate Reduction Test:

The methodology given for nitrate reduction testing using dermatophyte cultures corresponds with the methods reported in many research studies. Whereas the particular procedure is not mentioned in the offered circumstances, studies have emphasized the existence of nitrate-reducing fungi, including dermatophytes, capable of converting nitrate to nitrogen gaseous produced at various temperatures [25]. Additionally, the development of assays for detecting nitrate reduction, such as on-agar colony screening, has been reported, enabling the identification and isolation of nitrate-reducing bacteria, which could potentially include fungi with similar metabolic capabilities [26]. Furthermore, the development of halotolerant nitrate-reducing dermatophytes for wastewater denitrification highlights the broader applications of microbial nitrate reduction beyond dermatophytes [27]. Thus, although the procedure described here is appropriate for dermatophyte cultures, it may potentially provide insights into nitrate reduction by other fungi with similar metabolic pathways [28].

2.4.3. Carbohydrate Assimilation Tests:

The carbohydrate utilization test was performed to examine the dermatophyte and the fungal strain's selective utilization capability of a particular carbohydrate, according to the Kitanchaen and Hatai procedure. However, this

test was performed utilising HiCarbo™ Kit cassettes with various pH indicators (HiMedia, Mumbai, India), which included 31 different carbs such as simple sugar, sugar alcohol, and disaccharides. Fifty micro-litres of fresh active spore suspension (~ 104 CFU/mL) of the isolates, nHF-01 and PPR-01, were introduced to each reaction well and monitored for visual colour change every 24 hours for 10 days, following the manufacturer's instructions. An alteration in the color (according to manufacturer criteria) indicates a positive reaction. The well with a lack of sugar was utilized as a negative control [29]

2.4.4. Lipid And DNase Utilization Test:

Dermatophytes have enzymes that degrade lipids and DNA, so tests like the Lipid and DNA Utilization Assay are crucial for diagnosing their lipid and DNA degrading properties. However, to assay lipase and DNase production, we conducted halo degradation experiments on Petri dishes containing the respective substrates. We used disposable inoculation loops (1 µl) to place the inoculum in the center of Petri dishes that included culture medium for lipase (1000 ml distilled water, 10 g peptone, 5 g NaCl, 0.1 g CaCl₂, 20 g agar-agar, 10 ml Tween 20, pH 5.5) and for DNase (BD®, France) production tests. In both cases, cultures were maintained at 25 °C for 15 days.

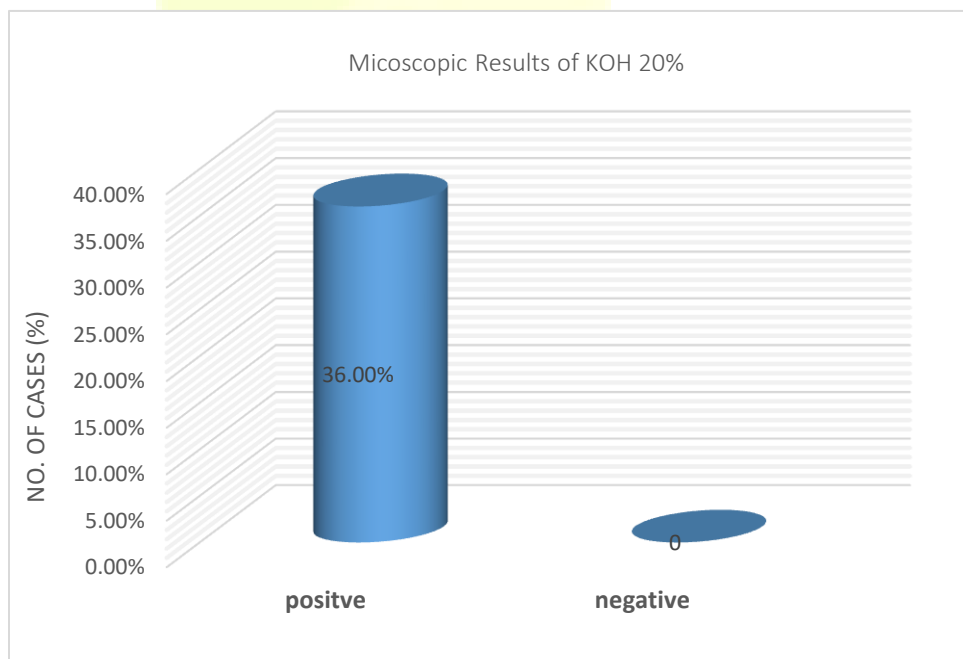
Positive samples for lipase production were identified by observing halo decomposition or precipitation of salt surrounding the colony. DNase readings were also based on observing halo formation caused by substrate degradation. However, it was essential to inject a 5N hydrochloric acid solution around the colonies and measure after 10 minutes. Enzymatic activity was assessed as the proportion of colony diameter to decomposition zone diameter [30].

2.4.5. Keratinase Activity Assay:

Dermatophytes are mould fungi well-known for their ability to synthesise keratinase enzymes, which have keratinolytic characteristics that break down the keratin in the skin tissue [31]. and to measure enzyme activity, Specialist testing such as keratinase activity assays are used. and a method involving the preparation of keratin-containing media, such as feather meal agar or keratin azure agar, is used [32]. This medium is then inoculated with dermatophyte cultures and incubated for 14–21 days at a temperature of 25–30 °C and Clear zones surrounding the colonies may be observed by researchers, indicating the activation of keratinase and the effective breakdown of keratin substrates [33].

3- RESULTS

In the Figures (1) and (2) showed the microscopic results of potassium hydroxide 20%, which were positive in 36 and negative in zero of the total 36 cases.



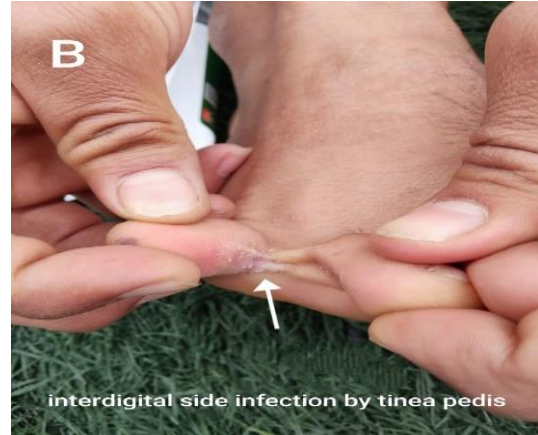


Fig 1: Distribution of clinically diagnosed athlete foot according to examination with KOH 20% Microscopic Result.

Fig 2: Represent (A) Microscopic examination of skin scraping with KOH 20% (B) The lateral interdigital web from athletes' foot infection by tinea pedis.

In the Figures (3) and (4) showed the culture results of SDA, which were positive in 36 (100%) and negative in no cases of the total 36 cases. Among the 36, culture-positive 36 (100%) were isolated.

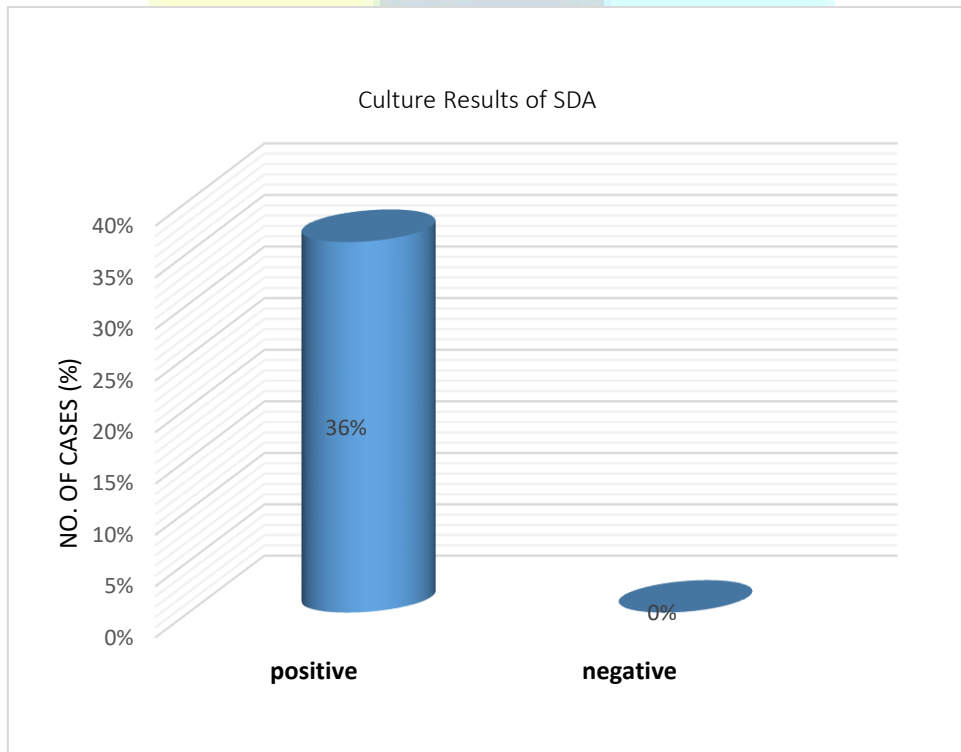

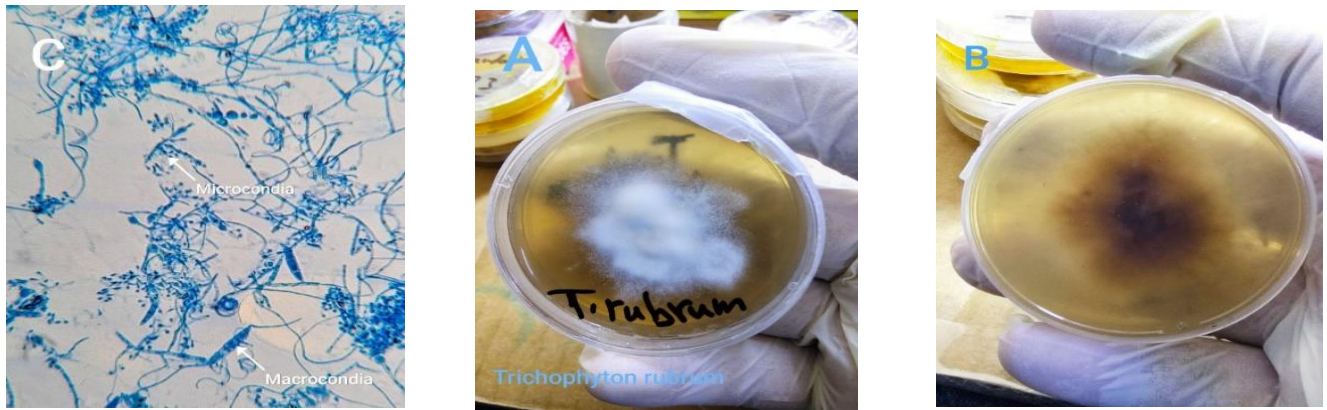


Fig 3: Distribution of clinically diagnosed Athletes' feet according to Sabouraud Dextrose Agar (SDA) culture results.

Fig 4: Represent Trichophyton rubrum after isolate from athletic foot growth on SDA (A)The top colonia are white to buff at first smooth becoming fluffy (B) The reverse colonia is pale, yellow or brown (C) Under Microscopic show micro and macroconidia.

Figures (5) and (6) demonstrated the culture results of DTM, which revealed that 32 (89%) of 36 cases were positive (red colour change) for dermatophytes in DTM, and 4 (11%) were negative (no colour change).

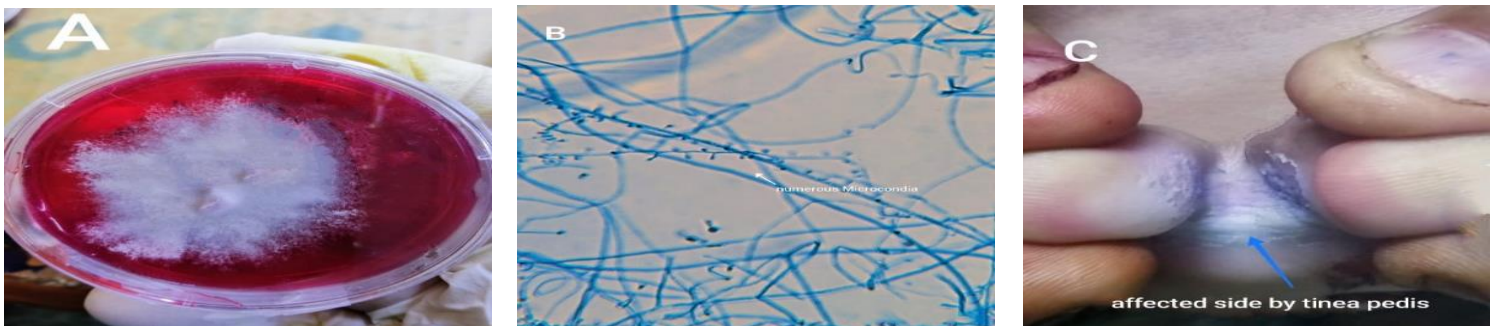
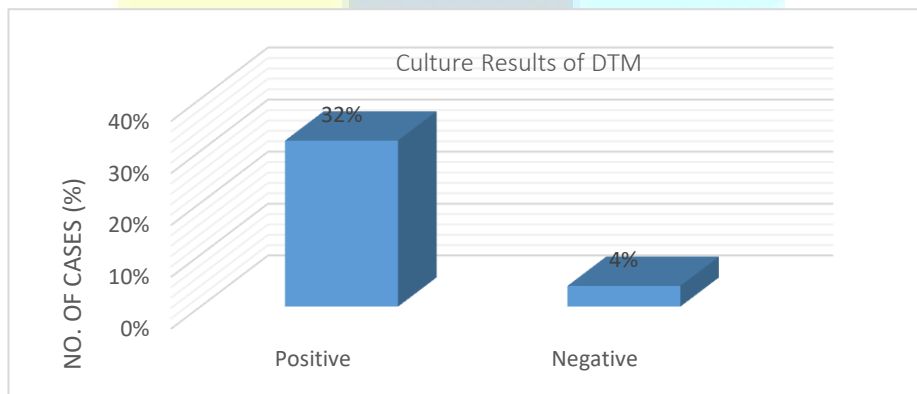


Fig 5: Distribution of Dermatophyte Test Medium (DTM) culture results.

Fig 6: Represent (A) Tinea pedis isolated from athlete foot growth on DTM while (B) T. rubrum with numerous microconidia under 40x microscopic examination and (C) clinically affected side between the interdigital web of toe.

Figure 7: describes the biochemical test results which revealed that 32 (89% of cases) of 36 cases were positive (Showing clear zones surrounding the colonies) for dermatophytes in keratinase and DNase, which revealed 4 (11% of cases) were negative (no Clear zones surrounding the colonies) while **Figure 8:** Represent colour change from yellow to pink result in the reduction Nitrate to Nitrite .on other hand, **Figure 9:** Represent Trichophyton mentagrophytes in urease test media show fluffy white grow indicated by the urease tests a colour change from (straw to pink) in the medium signified a positive test result, whereas no colour change was interpreted as negative

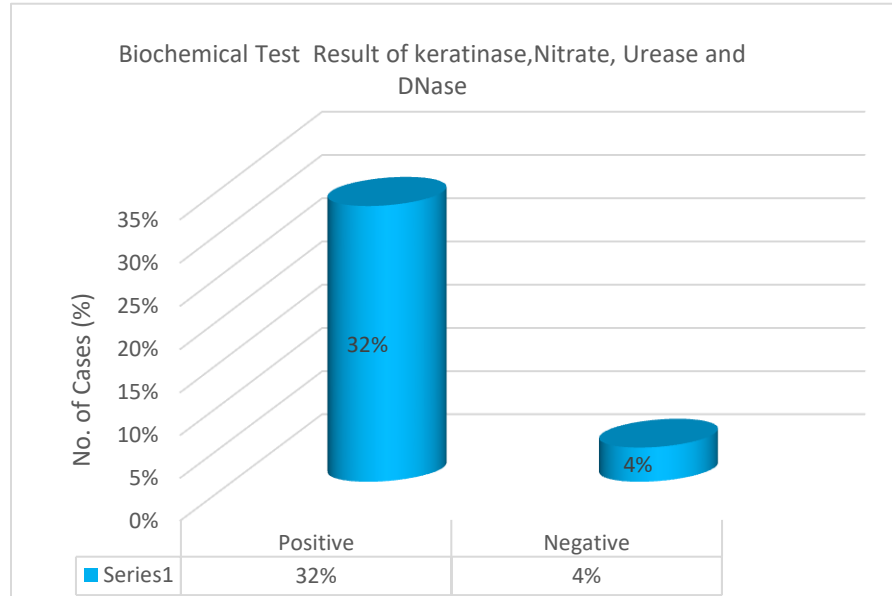


Fig 7: Distribution of clinically diagnosed athlete's feet according to biochemical test results of Keratinase, Nitrate, urease, and DNase culture.




Fig 8: Represent Nitrate reduction to Nitrite indicated by the colour change from yellow to pink (A) Negative result while (B) Positive results.

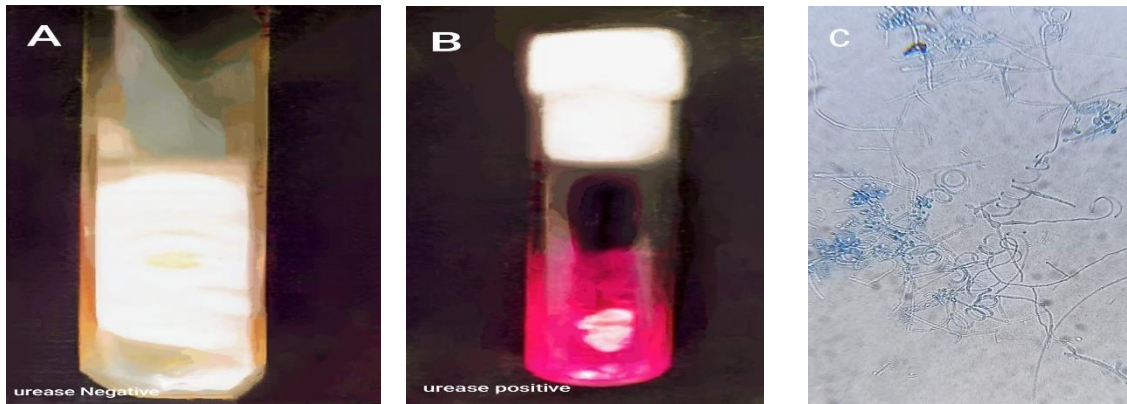


Fig 9: Represent growth Trichophyton mentagrophytes in urease test media which exhibit fluffy white colonies (A) Negative urease test with no colour change while (B) positive test result with a colour change from (straw to pink) (C) Microscopic appearances of LPCB trichophyton mentagrophytes.

Figures 10 and 11: demonstrate the culture results of the biochemical test which revealed that 30 (83%) of 36 cases were positive (Show clear zones surrounding the colonies) for dermatophytes in Carbohydrates and lipids 6 (17% of cases) were negative (no Clear zones surrounding the colonies).

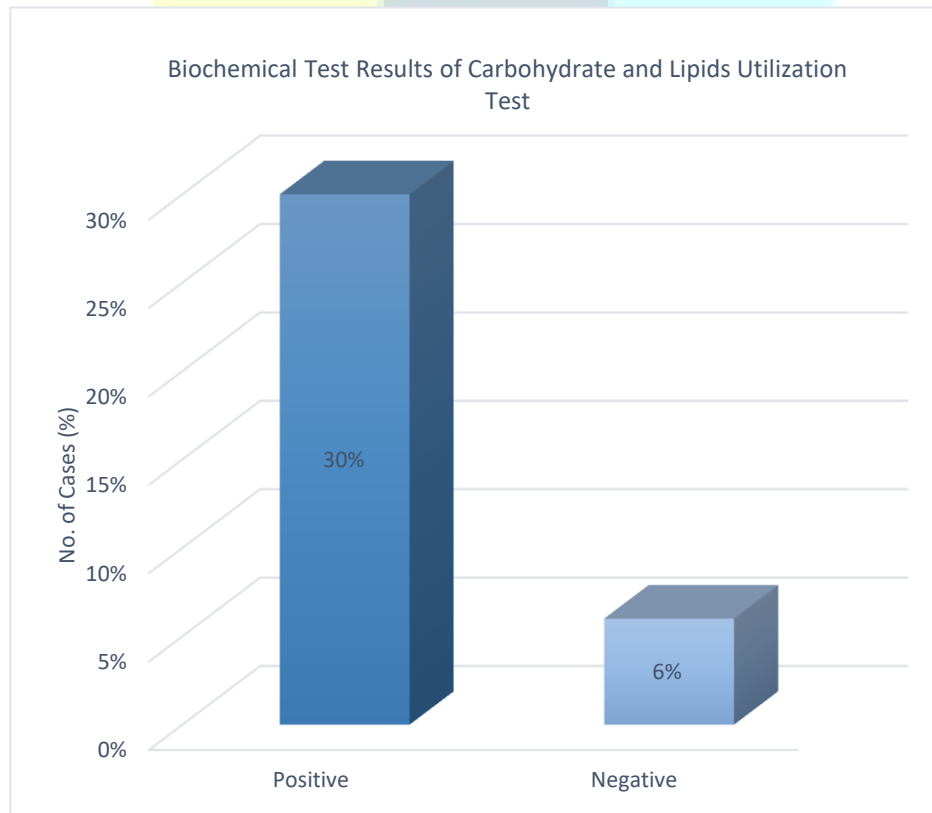


Fig 10: Distribution of clinically diagnosed Athlete's foot according to Biochemical Test with Carbohydrate and Lipid culture results.



Fig 11: Represent Lipase activity on lipid culture media (Tween 20) A clear halo zone appearance around the colony indicates lipase enzyme production by dermatophyte.

4- DISCUSSION

Based on data from the World Health Organization (WHO), dermatophytosis affects about 25 per cent of the global population, and its occurrence is greater in tropical locations because of the high temperature and humidity [34]. The increase in the species responsible for dermatophytosis may vary depending on geographic location, migration patterns across different continents, changes in human lifestyles, and medical approaches to treating dermatophytosis within various healthcare systems. All of these factors can influence the likelihood of developing a dermatophyte infection [35]. There are around 40 distinct species of dermatophytes and the contiguous nature of the dermatophyte infection facilitates its easy spread and impact on healthy individuals. The transmission from animals to humans is also high. Due to the highly contagious nature of these fungi, transmission can occur within the same body of an infected individual from one site to another [36]. This research aimed to identify the phenotypic characteristics of colonies growing in pure culture and the microscopic morphology of several types of dermatophytes that cause tinea pedis in athletes' feet at several sports clubs in Iraq by using several diagnosis procedures. This research comprised a total of 36 cases. There were 36 skin-scraping samples of the athlete's foot. When examined with KOH 20%, samples indicated the presence of dermatophytes. According to Figure (1) the direct microscopic examination using the KOH 20% test exhibited a 100% positive rate (36 out of 36 cases), demonstrating great sensitivity for detecting the causal agent of tinea pedis in skin scraping. This conclusion is consistent with previous research identifying the KOH test as a reliable diagnostic technique for fungal infections. For example, Cheng et al. (2020) [37]. Found a comparable positive rate in individuals with proven dermatophyte fungi infections. Zero negative cases improve the KOH test's reliability and sensitivity, making it the gold standard for initial screening, another recent investigation conducted (2021) included a study at Tikrit Teaching Hospital, which found that the KOH test demonstrated comparable sensitivity, highlighting its efficiency in the rapid and accurate detection of foot fungus as well as According to Figure (3) indicated the SDA culture results have a 100% (36 out of 36 positive cases) which is consistent with several studies highlighting the effectiveness of SDA as a standard medium for growing fungi. Research from Iraq also confirms the effectiveness of SDA in cultivating dermatophytes [38]. On the other hand, the Dermatophyte Test Medium (DTM) showed a slightly lower sensitivity of 89% (32 out of 36 positive samples). Existing research supports this finding, suggesting that DTM may be less sensitive than SDA due to its highly selective and specific characteristics for dermatophyte cultivation [39]. However, to confirm the diagnosis and differentiation of some species that infected athlete's foot using Biochemical tests according to Figures (7,8,9) Biochemical assays such as Urease, keratinase, Nitrate, and DNase have a sensitivity of 89% (32 out of 36 positive cases).

Each tests work as follows; the urease test measures urease synthesis, an enzyme that converts urea to CO₂ and ammonia. This enzyme is important for distinguishing dermatophyte species. The finding is consistent with previous research suggesting that urease plays a role in identifying *Trichophyton mentagrophytes*, a common *Tinea pedis* agent. According to a recent study in the *Journal of Clinical Microbiology*, the urease test is an effective tool for the diagnosis of dermatophytosis [40]. Keratinase is an enzyme that breaks down keratin, which is the key component of skin, hair, and nails. Previous research has shown that the synthesis of keratinase is common among dermatophytes. A recent study in *Mycoses* discovered that keratinase activity is crucial for the invasive potential of dermatophytes, making this test a reliable predictor of infection.

The DNase test identifies a fungus's ability to break down DNA, highlighting the importance of DNase in detecting dermatophytes that cause superficial infections [41].

This finding is consistent with previous research, which suggests that while biochemical assays are beneficial, they might not be as accurate as direct microscopy or culture procedures. Research published in the "*International Journal of Dermatology*" emphasized the heterogeneity in enzyme synthesis across various dermatophyte species, which might impair the sensitivity of these biochemical assays. On the other hand, other biochemical assays according to Figure (10, 11) which represented the lipids and carbohydrate utilization test analyze fungi's capacity to metabolize lipids and carbohydrates, which may help identify specific dermatophyte species. In our research, this test had an 83% positive rate (30 out of 36 samples) and a 17% negative rate (6 out of 36).

5- CONCLUSION

By definition, phenotypic approaches do not seem to provide a diagnostic challenge in identifying *tinea pedis*, particularly for Iraq's most often isolated dermatophyte species. During this investigation, biochemical assays were used to validate phenotypic approaches for several species. However, it seems insufficient in the presence of aberrant morphology or pleomorphism. However, our labs must use molecular approaches to identify and provide better treatment.

REFERENCES

- [1] Julien, G. A., et al. (2021). Dermatophytic diseases: A review of *Tinea pedis*. medRxiv. <https://doi.org/10.1101/2021.06.28.21259664>
- [2] Song, Y., & Li, R. (2024). Superficial fungal infections. In *Molecular Medical Microbiology* (pp. 2895-2904). Elsevier.
- [3] Abdalla, A., El-Sawy, H. S., & Ramadan, A. A. (2024). Emergence of advanced antifungal-delivery approaches for the treatment of *Tinea Pedis*. *ERU Research Journal*.
- [4] Sasagawa, Y. (2019). Internal environment of footwear is a risk factor for *tinea pedis*. *The Journal of Dermatology*, 46(11), 940-946. <https://doi.org/10.1111/1346-8138.15043>
- [5] Doğan, B., Akpolat, N. D., & Kutlubay, Z. (2023). Current approaches in the treatment of superficial fungal infections. *Journal of the Turkish Academy of Dermatology*, 17(4).
- [6] Chanyachailert, P., Leeyaphan, C., & Bunyaratavej, S. (2023). Cutaneous fungal infections caused by dermatophytes and non-dermatophytes: An updated comprehensive review of epidemiology, clinical presentations, and diagnostic testing. *Journal of Fungi*, 9(6), 669. <https://doi.org/10.3390/jof9060669>
- [7] Khalifa, A., et al. (2023). *Tinea unguium* and *tinea pedis* and their correlation with diabetes mellitus in the general population in the Hail Region, Saudi Arabia: A cross-sectional study. *Cureus*, 15(6). <https://doi.org/10.7759/cureus.40122>
- [8] Aliuddin, F., et al. (2023). Athlete's foot and associated risk factors: A cross-sectional mixed-methods study. *BMJ Military Health*. <https://doi.org/10.1136/bmjilitary-2023-002093>

- [9] Chemello, R. L., et al. (2023). Fungal infections. In *Dermatology in Public Health Environments: A Comprehensive Textbook* (pp. 293-338). Springer.
- [10] Lavari, A., Eidi, S., & Soltani, M. (2022). Molecular diagnosis of dermatophyte isolates from canine and feline dermatophytosis in Northeast Iran. *Veterinary Medicine and Science*, 8(2), 492-497. <https://doi.org/10.1002/vms3.759>
- [11] Aragón-Sánchez, J., et al. (2023). Onychomycosis and tinea pedis in the feet of patients with diabetes. *The International Journal of Lower Extremity Wounds*, 22(2), 321-327. <https://doi.org/10.1177/15347346221108197>
- [12] Wriedt, T. R., et al. (2023). Patients with tinea pedis and onychomycosis are more likely to use disinfectants when washing textiles than controls. *APMIS*, 131(11), 561-563. <https://doi.org/10.1111/apm.1327>
- [13] García-Lira, J. R., et al. (2024). Tinea pedis in adolescents: A comprehensive review. *Current Fungal Infection Reports*, 1-6. <https://doi.org/10.1007/s12281-023-00515-7>
- [14] Rasul, T. F., et al. (2022). Tinea pedis epidemiology and importance from the lens of homelessness and low-resource settings.
- [15] Yustisya, M. (2022). The comparison level of parent's knowledge towards interdigital tinea pedis (athlete's foot) in parents with and without interdigital tinea pedis in Namu Trasi. *Sumatera Medical Journal*, 5(3).
- [16] Alhadidi, S. N. A. (2022). Public understanding and awareness of insects in Iraq. *Journal of Entomological Research*, 46(4), 860-864. <https://doi.org/10.5958/0974-4576.2022.00088.1>
- [17] Brun, S., & Pihet, M. (2021). Laboratory diagnosis of dermatophytosis. In *Dermatophytes and Dermatophytoses* (pp. 355-374). Springer.
- [18] Bhabhor, U., Mistry, Y., & Mullan, S. (2022). Evaluation of sensitivity and specificity of direct microscopical examination of suspected mucor mycosis samples by potassium hydroxide (KOH) during Covid-19 Pandemic Era. *Advances in Infectious Diseases*, 12(4), 776-780. <https://doi.org/10.4236/aid.2022.124049>
- [19] Santhosh, P., George, M., & Nandakumar, G. (2022). Demonstration of fungi in superficial mycosis: Skin scraping and potassium hydroxide mount. *Journal of Skin and Sexually Transmitted Diseases*, 1-3. https://doi.org/10.25259/JSSTD_60_2022
- [20] Begum, J., et al. (2020). Recent advances in the diagnosis of dermatophytosis. *Journal of Basic Microbiology*, 60(4), 293-303. <https://doi.org/10.1002/jobm.201900737>
- [21] Falotico, J. M., & Lipner, S. R. (2022). Updated perspectives on the diagnosis and management of onychomycosis. *Clinical, Cosmetic and Investigational Dermatology*, 1933-1957. <https://doi.org/10.2147/CCID.S340547>
- [22] Agrawal, R., Faizan, S., & Gupta, P. (2024). Speciation and clinical classification of dermatophytosis in tertiary care hospital. *Pharm. Res.*, 5(2), 55-58.
- [23] Nwankwo, U. I., Edward, K. C., Udensi, C. G., & Onyeneke, P. U. (n.d.). Fungal colonization of body surfaces of youths living in Ikwuano LGA, Umuahia, Abia State, Nigeria.
- [24] Khan, S., et al. (2021). Isolation and identification of dermatophytes causing dermatophytosis at a tertiary care hospital in Bangladesh. *Archives of Clinical and Biomedical Research*, 5(3), 437-451.
- [25] Aldossari, N., & Ishii, S. (2021). Isolation of cold-adapted nitrate-reducing fungi that have potential to increase nitrate removal in woodchip bioreactors. *Journal of Applied Microbiology*, 131(1), 197-207. <https://doi.org/10.1111/jam.14984>

- [26] Bhusal, A., & Muriana, P. M. (2021). Isolation and characterization of nitrate reducing bacteria for conversion of vegetable-derived nitrate to 'natural nitrite'. *Applied Microbiology*, 1(1), 11-23.
- [27] Moloantoa, K. M., et al. (2023). Metagenomic assessment of nitrate-contaminated mine wastewaters and optimization of complete denitrification by indigenous enriched bacteria. *Frontiers in Environmental Science*, 11, 1148872. <https://doi.org/10.3389/fenvs.2023.1148872>
- [28] Curatolo, R., et al. (2021). Antifungal susceptibility testing of dermatophytes: Development and evaluation of an optimised broth microdilution method. *Mycoses*, 64(3), 282-291. <https://doi.org/10.1111/myc.13233>
- [29] Mandal, V., et al. (2021). Morpho-biochemical and molecular characterization of two new strains of *Aspergillus fumigatus* nHF-01 and *A. fumigatus* PPR-01 producing broad-spectrum antimicrobial compounds. *Brazilian Journal of Microbiology*, 52(2), 905-917.
- [30] Bonci, M. M., et al. (2021). In vitro virulence evaluation of clinical and environmental isolates of dermatophyte fungi. *Research, Society and Development*, 10(6), e21110615699-e21110615699. <https://doi.org/10.33448/rsd-v10i6.15699>
- [31] Bhari, R., & Kaur, M. (2023). Fungal keratinases: Enzymes with immense biotechnological potential. In *Fungal Resources for Sustainable Economy: Current Status and Future Perspectives* (pp. 89-125). Springer.
- [32] Gozali, C., Suryanto, D., & Hartanto, A. (2022). Partial purification and characterization of keratinase produced by keratinolytic fungi, *Earliella scabrosa* A2 and *Aspergillus flavus* A11. In *IOP Conference Series: Earth and Environmental Science*. IOP Publishing.
- [33] Maula, I. S., et al. (2023). Keratinase characterization of keratinase producing microbes from peat soil Palangka Raya, Central Kalimantan. In *AIP Conference Proceedings*. AIP Publishing.
- [34] Petrucelli, M. F., et al. (2020). Epidemiology and diagnostic perspectives of dermatophytoses. *Journal of Fungi*, 6(4), 310. <https://doi.org/10.3390/jof6040310>
- [35] Bontems, O., et al. (2020). Epidemiology of dermatophytoses in Switzerland according to a survey of dermatophytes isolated in Lausanne between 2001 and 2018. *Journal of Fungi*, 6(2), 95. <https://doi.org/10.3390/jof6020095>
- [36] AL-Khikani, F. H. O. (2020). Dermatophytosis a worldwide contiguous fungal infection: Growing challenge and few solutions. *Biomedical and Biotechnology Research Journal (BBRJ)*, 4(2), 117-122. https://doi.org/10.4103/bbrj.bbrj_79_20
- [37] Aboul-Ella, H., Hamed, R., & Abo-Elyazeed, H. (2020). Recent trends in rapid diagnostic techniques for dermatophytosis. *International Journal of Veterinary Science and Medicine*, 8(1), 115-123. <https://doi.org/10.1080/23144599.2020.1767414>
- [38] Al-Mahmood, A., & Al-Sharifi, E. (2021). Epidemiological characteristics and risk factors of Tinea Pedis disease among adults attending Tikrit Teaching Hospital, Iraq. *Infectious Disorders - Drug Targets*, 21(3), 384-388. <https://doi.org/10.2174/1871526520666201218102823>
- [39] Leung, A. K., et al. (2023). Tinea pedis: An updated review. *Drugs in Context*, 12. <https://doi.org/10.7573/dic.212322>
- [40] Ates, A. N., Ozcan, K., & Ilkit, M. T. (2008). Diagnostic value of morphological, physiological and biochemical tests in distinguishing *Trichophyton rubrum* from *Trichophyton mentagrophytes* complex. *Medical Mycology*, 46(8), 811-822.
- [41] Moskaluk, A. E., & VandeWoude, S. (2022). Current topics in dermatophyte classification and clinical diagnosis. *Pathogens*, 11(9), 957. <https://doi.org/10.3390/pathogens11090957>

التوصيف المظهري لعزل وتحديد سعفة القدم في اقدام الرياضيين

الخلاصة

سعفة القدم، او "قدم الرياضي"، هي عدوى فطرية تغزو المنطقة بين أصابع القدم. وعلى الرغم من انه مرض منتشر، فقط يكون غياب المعلومات حول انتقاله وعوامل الخطر وخيارات الرعاية الصحية بين الناس ذو أهمية في البحث والتمحيص.

هدفت الدراسة الحالية الى إيجاد التوصيف المظهري لبعض الفطريات الجلدية في أقدام الرياضيين.

شمل البحث 36 رياضيا مشاركا في العراق تم تسليم الاستبيان للرياضيين في المراكز والأندية الرياضية في الفترة من ديسمبر 2023 الى يوليو 2024 وتم أخذ عينات الجلد مجهريا في تركيب هيدروكسيد البوتاسيوم بنسبة 20% وتم استخدام أوساط لزراع الفطريات الجلدية مثل وسط الزرع SDA و DTM وتم استخدام صبغة قطن اللاكتوفينول الأزرق والفحوصات الكيمياء الحيوية مثل فحص Urease وغيرها من الاختبارات للتمييز بين نتائج العينات المجهرية.

تبين أن ما مجموعه 36 حالة من تشخيص الرياضيين ان KOH و SDA هي 100% بينما عند استخدام الوسط الانتقائي مثل DTM تكون 89%. من ناحية أخرى باستخدام الاختبارات الكيمياء الحيوية مثل DNase, Keratinase, Nitrate, Urease, تكون 89% بينما اختبارات الدهون والكربوهيدرات تكون 83% تكشف عن تمايز في الصفات المظهري حسب الأنواع المختلفة لعوامل العدوى بالفطور الجلدية.

ان الطرق التشخيص التقليدية غير كافية في اختلاف وتعدد الاشكال ومع ذلك، يجب على مختبراتنا استخدام الطرق الجزيئية لتحديد المسبب وتوفير أفضل العلاج .