

Diagnostic Efficiency of MRI in Evaluation of Sphenoid Sinus Mucocele Complications

Dunya Ali Mustafa *

Department of Radiological Techniques, Health and Medical Techniques College, Middle Technical University, Baghdad, Iraq

Article Info	ABSTRACT
<p>Article history:</p> <p>Received January, 16, 2026 Revised January, 23, 2026 Accepted February, 05, 2026</p> <hr/> <p>Keywords:</p> <p>Sphenoid Sinus Mucocele, Complications, MRI Diagnosis</p>	<p>Sphenoid sinus mucocele is a benign expansile mucus-filled cystic lesion as a result of chronic obstruction of the sinus ostium, that may affect adjacent important structures and cause optic nerve and intracranial structures becoming involved. The study aimed to assess the effectiveness of MRI in identifying the disease and its complications through demographic factors age and sex. The study was conducted on (42) patients with sphenoid sinus mucocele (20 males and 22 females), aged (1-75) years in the Medical City Complex (Ghazi Hariri Hospital), Baghdad, Iraq during the period from January to July 2025. MRI machine with 1.5 Tesla from (Achieva, Philips Medical Systems) was used to examine the patients in the study. The results revealed that males were more likely to have complication more than females ($p=0.001$). The patients mean age was (36.5) years, and younger patients were more susceptible to the disease than the elderly with a highly significant difference ($p<0.001$). The highest incidence rate was in cavernous sinuses thrombosis 5 (11.9%), while the lowest incidence rate was in intracranial abscess and cerebrospinal fluid leakage 1 (2.4%). The study demonstrated that MRI had a high efficiency in diagnosing the disease in terms of sensitivity, specificity, and accuracy (96%), (91%), and (95.2%) respectively. Males are more likely to develop sphenoid sinus mucocele than females, while young patients are more susceptible to the disease. MRI has a high ability to diagnose sphenoid sinus mucocele and its complications and determine the factors that may affect infection.</p>
<p>Corresponding Author:</p> <p>* Dunya Ali Mustafa Department of Radiological Techniques, Health and Medical Techniques College, Middle Technical University, Baghdad, Iraq Email: dunya.ali@mtu.edu.iq</p>	

1- INTRODUCTION

The sphenoid sinus is considered one of the important structures in the human body because of its important role in filtering and humidifying the air entering the human body [1]. However, when it is affected, fluids will begin to accumulate inside it, and this leads to the obstruction of the passages that help to filter the air [2]. The accumulation of these fluids leads to an increase in the size of the sinus and thus an increase in pressure inside the skull or erosion of the structures adjacent to the sinus. These will lead to certain symptoms such as vision disturbance or neuropathy [3]. Therefore, the earlier diagnosis will help in reducing or eliminating the complications that may occur when the disease worsens.

Computed tomography is considered one of the most effective and essential devices in detecting sinus diseases, as it plays a fundamental role in diagnosing bones [4,5]. However, its effectiveness is less in the case of diagnosing tissues, especially when complications of the disease occur and it extends to adjacent tissues [6]. Consequently, there is a need to use magnetic resonance imaging (MRI) in assessing complications of the disease, as it plays an important and effective role in diagnosing tissues and thus detecting disease progression [7].

Therefore, the efficiency of MRI in diagnosing the disease is considered equal to or less than that of CT scans [8]. Hence, determining the efficiency of the device is important to determine which is better. For that reason, the research aim was to assess the MRI device in detecting sphenoid sinus mucocele complications.

2- MATERIALS AND METHODS

The study was carried out on (42) patients with sphenoid sinus mucocele (20 males and 22 females), aged (1-75) years, and were all examined with a CT scan in the Medical City Complex (Ghazi Hariri Hospital), Baghdad, Iraq during the period from January to July 2025. MRI machine with 1.5 Tesla from (Achieva, Philips Medical Systems) was used to examine the patients in the study. Patients who suffered from visual disturbances, headaches, and sinus obstruction were included in the study, while patients who had a previous cancer, or metals in their bodies, or had fear of MRI, or did not complete the examinations, such as clinical or imaging data were excluded.

The MRI examination was done by lying the patients on the MRI table, with the head coil placed, and then protocols were used including different sequences: T1-axial (TR=400 ms, TE=8 ms), T2-axial (TR=3000 ms, TE=96 ms), sagittal T2, axial T2 Short Tau Inversion Recovery (STIR), axial T2-weighted Fluid-Attenuated Inversion Recovery (FLAIR), and Diffusion-Weighted Imaging (DWI). Standardized imaging parameters across all machines included a slice thickness of 3 mm, a field of view (FOV) of 230 mm, and 256×256 matrix size. The radiographic images were confidentially evaluated by three radiologists with over 10 years of experience based on the shape of the sinus and the signal intensity during the examination. High resolution on T1 and T2 images indicated that mucocele had accumulated in the area. The bone condition was also evaluated to determine if there was erosion of the structure, which indicates advanced disease and increased pressure on intracranial structures. Neighbouring structures, such as the eye and cavernous sinus, were then evaluated to determine if the disease had progressed and penetrated into the adjacent structures as shown in Figure 1. The study was approved by the Training and Human Development Center at the Medical City, Ministry of Health, Baghdad, and all patients agreed to provide information about their disease, while keeping patients' information confidential.

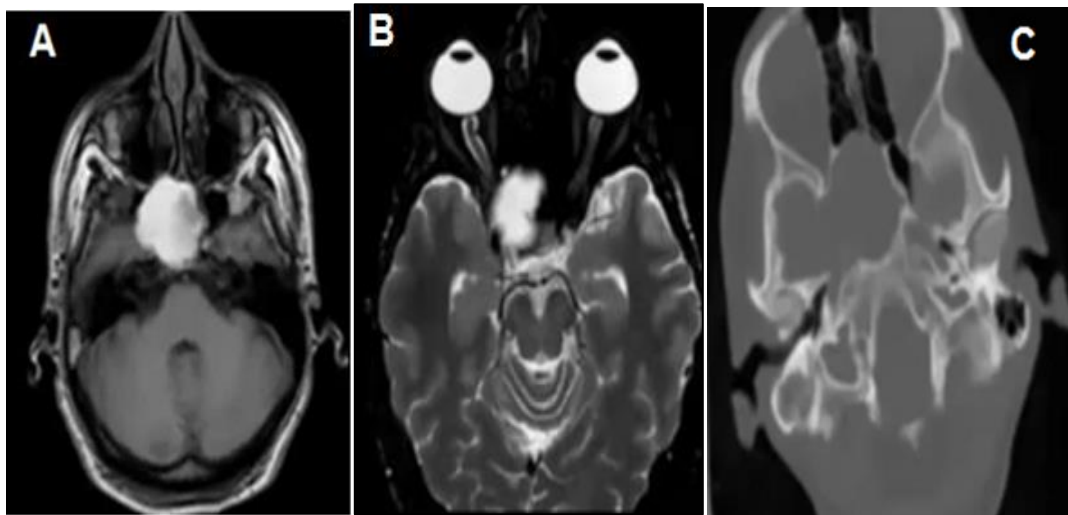

Fig (1): A female, 38 years old, with right-side papilledema A) An Axial T1 weighted image shows large mucocele in the right side of the sphenoid sinuses with high signal intensity. B) An MRI axial T2 SPIR image shows symmetry between the right and left perioptic nerve sheaths, indicating papilledema. C) An Axial CT image for the same patient shows the sphenoid sinuses mucocele with destruction and bone erosion

Statistical Analysis: The statistical analysis program SPSS version 20 was used for data analysis. The study population was determined by frequencies and percentages (%). The Chi-square test, Fisher's exact test and Mann-Whitney test were employed to evaluate and compare the age, gender and MRI results. The ($p < 0.05$) was regarded as statistically significant.

3- RESULTS AND DISCUSSION

The chi-square test results in Table 1 showed a heterogeneous pattern of complication distribution among patients, where the complications had a significant difference of ($\chi^2=44.0$) at ($p < 0.001$). The most common group was patients have mucocele without complications 12(28.6%), followed by cavernous sinus thrombosis (16.7%), while other complications, such as papilledema, meningitis, and optic nerve compression, accounted for (9.5%) each. Less specific findings were intracranial abscess (7.1%), bone erosion, CSF leak, and comorbidities (such as meningitis with abscess or CSF leak), with ($\leq 2.4%$) frequencies.

Table (1): The Complication types of Sphenoid Sinus Mucocele

Complication Type	N (%)	Chi-square (χ^2) (<i>p</i> -value)
Cavernous sinuses thrombosis	7(16.7%)	44.0 0.00003*
Optic nerve compression	4(9.5%)	
Meningitis	4(9.5%)	
Papilledema	4(9.5%)	
Intracranial abscess	3(7.1%)	
Bone erosion	1(2.4%)	
CSF leak	1(2.4%)	
No complications	12(28.6%)	
Cavernous sinuses thrombosis and optic nerve compression	1(2.4%)	
Meningitis and intracranial abscess	1(2.4%)	
Meningitis and CSF leak	1(2.4%)	
Bone erosion and papilledema	1(2.4%)	
Pituitary dysfunction and optic nerve compression	1(2.4%)	
Intracranial abscess and CSF leak	1(2.4%)	
Total	42(100%)	

* $p < 0.001$: statistically significant (Chi-square goodness-of-fit test)

The results of Fisher's Exact test showed that there are differences between gender and the results of magnetic resonance imaging (Fisher's Exact Test) at ($p=0.0036$). In the male group, the percentage of positive findings was (45.2%), while the percentage of negative findings was (2.4%), whereas in females, the presence of complications was equal as positive and negative findings were in (26.2%). The results showed that male patients were more susceptible to complications of mucocele, with positive outcomes being higher in males, as observed in Table 2.

Table (2): The relationship between gender and MRI findings in patients with sphenoid sinus mucocele

Gender	MRI Negative N (%)	MRI Positive N (%)	Total N (%)	p-value
Male	1 (2.4%)	19 (45.2%)	20 (47.6%)	0.0036*
Female	11 (26.2%)	11 (26.2%)	22 (52.4%)	
Total	12 (28.6%)	30 (71.4%)	42 (100%)	

Fisher's Exact Test, $p=0.001$. MRI: magnetic resonance imaging

* Statistically significant at $p < 0.05$

The findings of Mann-Whitney test showed a statistically significant relationship between the age and lesion variables ($Z = -4.493$) at ($p < 0.001$), as the mean age was (34.42) years for the group of patients with negative lesions, while the mean age was (16.33) years for the patients with positive lesions. This indicates that younger people (mean age < 30 years) had positive lesions, while older people (mean age 60 years) had negative MRI results as shown in Table 3 and Figure 2.

Table (3): Comparison of age between MRI-Negative and MRI-Positive groups

MRI Results	N (%)	Mean Rank	Mann–Whitney U		Z-value	p-value
Negative	12 (28.6%)	34.42				
Positive	30 (71.4%)	16.33				
Total	42 (100%)	–	25		-4.493	<0.001*

* ($p < 0.001$): Statistically significant

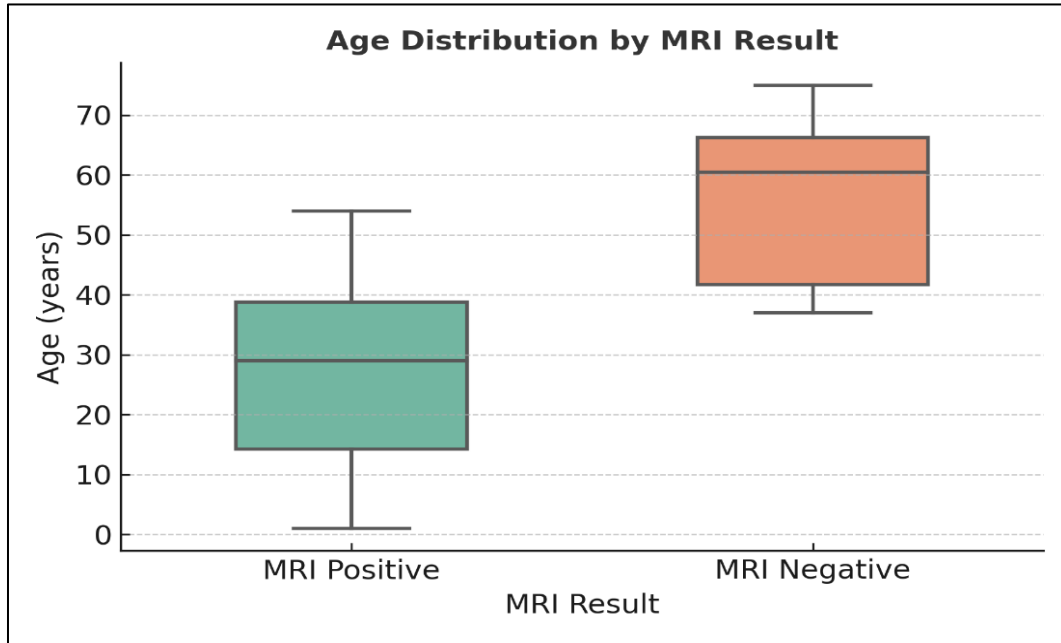


Fig (2): Age distribution by MRI result in patients with Sphenoid Sinus Mucocele

The results of sphenoid sinus mucocele examination by MRI showed that it is highly effective in detecting sinus complications, especially with regard to the extension of the disease to the adjacent tissues, compared to the CT scan, which is considered one of the devices used as the gold standard in diagnosing these complications, especially with regard to the bones, where the sensitivity was (96%) and the specificity (91%) with an accuracy of (95.2%), while negative predictive value was (91%) and the positive predictive value (96%) as shown in Table 4.

Table (4): Diagnostic accuracy of MRI compared with computed tomography (CT) in the evaluation of sphenoid sinus mucocele

Comparison	TP	FN	TN	FP	Sensitivity (%)	Specificity (%)	Positive Predictive Value (%)	Negative Predictive Value (%)	Accuracy (%)
MRI vs. CT	29	1	11	1	96	91	96	91	95.2

TP = True positive; FN = False negative; TN = True negative; FP = False positive. Computed Tomography was considered the reference standard test.

In Figure 3, the ROC curve showed that MRI has a high efficiency in distinguishing the disease, as the area under the curve (AUC) was (94.29%), which indicated the high ability in diagnosis. Also, the upper height of the curve with stability in the first quarter indicated the sensitivity and accuracy of the magnetic resonance imaging device in diagnosing the disease, and this finding was also confirmed in Table 4, indicating the reliability of the device in diagnosing the disease, as the AUC was higher than (0.90).

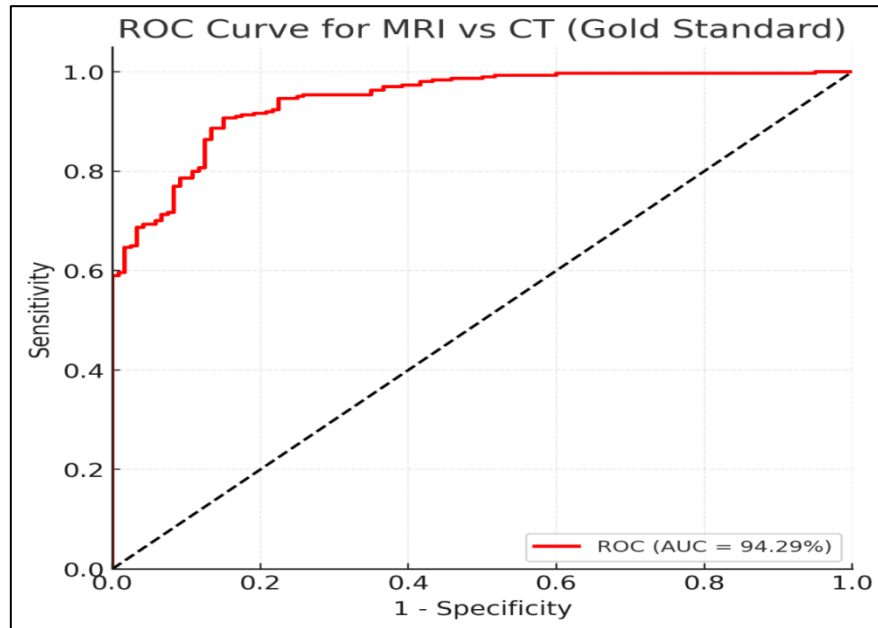


Fig (3): Receiver Operating Characteristic (ROC) Curve showing the diagnostic accuracy of MRI compared with CT (Gold Standard) in patients with sphenoid sinus mucocele

This study is considered one of the first investigations to diagnose sphenoid sinus mucocele complications using MRI [9]. The study showed that the most common complication was cavernous sinus thrombosis. This result was consistent with Villa *et al.*, 2014, who showed that the high incidence of complications was cavernous sinus thrombosis due to the close anatomical location of each structure, also the close venous drainage between them [10]. In the same way, the most common complications were optic nerve compression, papilledema, and meningitis, which was consistent with Ibrahim *et al.*, 2024, who showed that the close proximity between the structures is the main reason for these complications, as the bony orbit is located anterior to sphenoid sinus, and the optic nerve is on the side of the sphenoid sinus wall. Therefore, the worsening of the patient's health condition will lead to visual impairment as a result of pressure on the optic nerve [11]. Thus, early diagnosis helps in very quickly treatment and avoids permanent vision loss [12]. Similarly, meningitis can occur as a result of the anatomical proximity of the sphenoid sinus and the central nervous system. As a result of this proximity, the disease can extend to adjacent structures [13]. The same applies to intracranial abscess complications. This means that early diagnosis of the disease reduces the incidence of strokes and preserves neurological and visual functions [14].

The study revealed that bone erosion and cerebrospinal fluid leakage are among the least common complications this decrease indicates that the diagnostic tools that used, magnetic resonance imaging (MRI) and computed tomography (CT) scans, are highly sensitive in detecting the disease in its early stages. Therefore, using these imaging tools in screening helps to determine the progression of the disease and prevent bone damage, this result contradicts the findings of Slevakumar *et al.*, 2015, who considered bone erosion to be a common complication of mucoceles of the sphenoid sinus, occurring as a result of compression of the skeletal structures adjacent to the sinus due to disease progression, which leads to bone erosion, and the growth of the mucocele exerts pressure on the bony wall, resulting in bone erosion and subsequent cerebrospinal fluid leakage, which manifests as nasal secretions [15]. The study also demonstrated that some combined complications were common, such as cavernous sinus thrombosis and optic nerve compression. This finding in line with those of Yu *et al.* 2021 and Pajić *et al.*, 2017 who showed that these complications occurred as a result of the closeness of the structures to each other [16,17], and as a result of these complications, the patient may be exposed to visual disturbances [18].

Moreover, other combined complications were meningitis and intracranial abscesses leading to loss of sensation in one of the extremities [19]. Also, the occurrence of meningitis with cerebrospinal fluid leakage in this study was consistent with the study of [20,21], who showed that cerebrospinal fluid leakage can occur as a result of intracranial pressure, and as a result of these leaks, the central nervous system may be affected leading to meningitis [22]. Also, our findings showed that the relationship between bone erosion and papilledema increased intracranial pressure leading to bone erosion which is consisted with [23], who suggested that visual impairment is caused by optic nerve

compression. This indicates the necessity of avoiding the occurrence of complications in order to maintain bone integrity and avoid the occurrence of intracranial pressure [24]. The study showed a close association between sex and the sphenoid sinus mucosa, showing that males had more positive results, which agreed with the finding of [25,26], who showed that most positive lesions were in males, although most lesions were in women. These results may have been the result of hormonal and anatomical differences, which led to a different distribution of lesions between women and men. The results showed that most sphenoid sinus mucocele complications were observed among young people, which was similar to study done by Barbellini *et al*, 2022, who showed that most complications were in people aged (15 - 29) years [27].

One study reported that the reason for this difference is the result of changes in tissue structure and function, which may change with age, as these changes may not appear on MRI, and thus negative results appear in the elderly [28]. This study showed that MRI has a high potential to diagnose sphenoid sinus mucocele and its complications, which is consistent with Bola *et al*, 2021, who stated that MRI has the ability to diagnose tissues more accurately than CT, despite the fact that one false negative case was not diagnosed by MRI [29]. This result does not diminish the importance of this examination however, a clinical examination of the patient must be taken to avoid such cases [30], while the specificity was high, MRI is able to distinguish between the disease and other conditions like tumors, which may show similar symptoms. Since the homogeneity of the mucocele, distinguishing between cases is necessary for treatment [31]. The results showed that there is a false positive case, and this is consistent with Nardi *et al*, 2022, who showed that such cases may occur as a result of the protein content inside the sinus [32]. This may change the signal received by the MRI, as the signal intensity is affected by the protein present inside the sinus, as the signal appears high in T1 and T2 when there is a small amount of protein [33].

A high current value indicates negative results, which means that the patient cannot have the disease, thus avoiding further examinations. This indicates the importance of MRI in imaging tissue diseases. The study was limited by a small sample size due to the rarity of the disease. Although the sample size of 42 patients may seem small for giving definitive epidemiological conclusions, it is considered an important group for studying a rare and significant disease, and therefore further research should use a larger sample size also expands the study to include many diseases like nasal polyps, as well as adding new imaging devices to detect the disease in faster and earlier ways, thus achieving the best results.

4- CONCLUSION

The study concluded that the most common complication was cavernous sinus thrombosis, while the least common complication was bone erosion with cerebrospinal fluid leakage, and the younger people were also more likely to have it. They are the most affected, and males were more likely to developed complications more than females. Magnetic resonance imaging (MRI) has shown high efficiency in diagnosing the disease and its complications.

REFERENCES

- [1] Peng, X. L., Yue, Z. Z., Zhang, Y. L., & Sun, P. Y. (2023). Nasal sinus mucoceles manifesting ocular symptoms. *Journal of Craniofacial Surgery*, 34(2), e141–e145. <https://doi.org/10.1097/SCS.00000000000008888>
- [2] Nam, K., & Seo, M. Y. (2024). Isolated sphenoid fungal sinusitis with mucocele mistaken for chordoma: A study of two unique cases. *Journal of Rhinology*, 31(1), 37–41. <https://doi.org/10.18787/jr.2023.00070>
- [3] Chowdhury, R., Aldajani, A., Almhanedi, H., Al Majid, D., Tewfik, M. A., & Himdi, L. (2025). Paranasal sinus mucoceles with intraorbital and intracranial involvement: A case series analysis and surgical outcomes assessment. *Annals of Otology, Rhinology & Laryngology*, 134(3), 225–233. <https://doi.org/10.1177/00034894241300806>
- [4] Higashino, M., Abe, S., Sawada, M., Yamada, H., Ayani, Y., Haginomori, S. I., ... Tanaka, E. (2022). Development of the sphenoid sinus in Japanese children: A retrospective longitudinal study using three-dimensional computed tomography. *Journal of Clinical Medicine*, 11(21), 6311. <https://doi.org/10.3390/jcm11216311>

- [5] Hassan, N. A., Ah Mahdi, M., & Irhyyim, N. S. (2024). Correlation between sphenoid sinus pneumatization and sella turcica dimensions using computed tomography. *Journal of International Medical Research*, 52(10), 03000605241287021. <https://doi.org/10.1177/03000605241287021>
- [6] Dedushi, K., Hyseni, F., Musa, J., Saliqaj, K., Vokshi, V., Guy, A., ... Shatri, J. (2021). Importance of MRI in the diagnosis of a rare intracranial mucocele associated with frontal paranasal osteoma: Case report and literature review. *Radiology Case Reports*, 16(10), 3094–3098. <https://doi.org/10.1016/j.radcr.2021.07.038>
- [7] Sommer, F. (2021). Rare diseases of the nose, the paranasal sinuses, and the anterior skull base. *Laryngo-Rhino-Otologie*, 100(Suppl 1), S1. <https://doi.org/10.1055/a-1331-2469>
- [8] Gökçe, E., & Beyhan, M. (2022). Advanced magnetic resonance imaging findings in salivary gland tumors. *World Journal of Radiology*, 14(8), 256–? <https://doi.org/10.4329/wjr.v14.i8.256>
- [9] Severino, R., & Severino, P. (2017). Fronto-orbital mucocele with intracranial extension: A case report. *Journal of Surgical Case Reports*, 2017(6), rjx107. <https://doi.org/10.1093/jscr/rjx107>
- [10] Villa, A., De Angelis, M., Piscevic, I., Solari, D., Cavallo, L. M., & Cappabianca, P. (2014). Sphenoid sinus mucocele caused by a completely thrombosed intracavernous carotid artery aneurysm: An unusual association. *Journal of Neurological Surgery Reports*, 75(1), e108–e112. <https://doi.org/10.1055/s-0034-1373666>
- [11] Ibrahim, M., Alqunae, M., Najibullah, M., Shabbir, Z., & Azab, W. A. (2024). Isolated sphenoid sinus fungal mucoceles: A rare entity with a high propensity for causing neurological complications. *Surgical Neurology International*, 15, 444. https://doi.org/10.25259/SNI_849_2024
- [12] AlMomen, A., Alali, M., Alkhalidi, S. K., Alsheef, H., Aldhurai, A., & Alawami, B. (2021). Isolated sphenoid lesions. *American Journal of Otolaryngology and Head & Neck Surgery*, 4(4), 1134.
- [13] Sidam, S., Gupta, V., & Kumar, A. (2022). Mucopyocele: An entity infrequently reported as a complication of functional endoscopic sinus surgery. *Indian Journal of Otolaryngology and Head & Neck Surgery*, 74(Suppl 2), 1310–1313. <https://doi.org/10.1007/s12070-021-02430-1>
- [14] Sigüenza González, R., Pérez Fernández, S., Jiménez Cuenca, I., & Castañeda Cruz, C. (2019). Facial mucocele and brain complications: Diagnostic priorities. *BJR Case Reports*, 5(4), 20190006. <https://doi.org/10.1259/bjrcr.20190006>
- [15] Selvakumar, A., Mahalaxmi, B., Ananth, V., & Gautam, C. (2014). Sphenoidal mucocele causing bilateral optic neuropathy and ophthalmoplegia. *Indian Journal of Ophthalmology*, 62(4), 515–517. <https://doi.org/10.4103/0301-4738.99863>
- [16] Yu, J. C., Buchman, S. R., Gosain, A. K., Havlik, R. J., Wang, T. H., Lam, P. S., & Masoumy, M. (2021). Basic biomechanics for craniofacial surgeons: The responses of alloplastic materials and living tissues to mechanical forces. *FACE*, 2(4), 446–461. <https://doi.org/10.1177/27325016211060232>
- [17] Pajić, S., Boljević, T., Antić, S., Mrvaljević, M., Cojić, M., Janić, J., & Pešić, Z. (2017). Proptosis and diplopia as consequences in trauma of craniofacial junction. *Facta Universitatis, Series: Medicine and Biology*, 19(1), 38–44. <https://doi.org/10.22190/FUMB170517006P>
- [18] Rama Raj, P., & Smith, V. (2021). Anatomical basis of clinical manifestations seen in cavernous sinus syndrome: A narrative review. *The Open Ophthalmology Journal*, 15(1), 70–? <https://doi.org/10.2174/1874364102115010070>
- [19] Karpishchenko, S., Arustamyan, I., Stancheva, O., & Kaplun, D. (2024). Sphenoid sinus disease in geriatric patients: An analytical approach. *Procedia Computer Science*, 231, 258–266. <https://doi.org/10.1016/j.procs.2023.12.201>
- [20] Sheikh, S., Ho, M. L., Eisner, M., Gushue, C., Paul, G., Holtzlander, M., ... Lind, M. (2023). Elexacaftor-tezacaftor-ivacaftor therapy for chronic sinus disease in cystic fibrosis. *JAMA Otolaryngology–Head & Neck Surgery*, 149(12), 1075–1082. <https://doi.org/10.1001/jamaoto.2023.2701>

- [21] Jung, J. H., Cho, G. S., Chung, Y. S., & Lee, B. J. (2013). Clinical characteristics and outcome in patients with isolated sphenoid sinus aspergilloma. *Auris Nasus Larynx*, 40(2), 189–193. <https://doi.org/10.1016/j.anl.2012.07.008>
- [22] Bubshait, R. F., Almomen, A. A., & Moumen, A. A. (2021). The endonasal endoscopic management of cerebrospinal fluid rhinorrhea. *Cureus*, 13(2), e13457. <https://doi.org/10.7759/cureus.13457>
- [23] Gokani, S., Kumaresan, K., Adari, S., Ergisi, M., Oludeye, O., Jegatheeswaran, L., & Philpott, C. (2024). The clinical course of paranasal sinus mucocoeles—A retrospective case series. *Journal of Clinical Medicine*, 13(2), 397. <https://doi.org/10.3390/jcm13020397>
- [24] Sileo, G., Valentini, M., Gravante, G., Monti, G., Arosio, A. D., Bignami, M., ... Turri-Zanoni, M. (2023). Sinonasal malignancies involving the frontal sinus: A mono-institutional experience of 84 cases and systematic literature review. *Journal of Clinical Medicine*, 12(9), 3186. <https://doi.org/10.3390/jcm12093186>
- [25] Mohamed, E. M., Rehan, O. M., Elhadidy, M. S., & Elhadidy, M. S. (2025). CBCT analysis of septation and extension of sphenoid sinus in a sample of the Egyptian population: A retrospective study. *Advanced Dental Journal*, 7(2), 172–182. <https://doi.org/10.21608/adjc.2025.338907.1664>
- [26] Barbiellini Amidei, C., Salmaso, L., Bellio, S., & Saia, M. (2022). Epidemiology of traumatic spinal cord injury: A large population-based study. *Spinal Cord*, 60(9), 812–819. <https://doi.org/10.1038/s41393-022-00795-w>
- [27] de Mendonça, D. S., Newman, N. I., Leite, J. E. R., Ribeiro, E. C., Gurgel, M. L., Júnior, C. M. C., ... Costa, F. W. G. (2024). Surgical-related morphological characteristics of sphenoid sinuses: A comprehensive CT-based analysis. *Journal of Clinical and Experimental Dentistry*, 16(12), e1445. <https://doi.org/10.4317/jced.62099>
- [28] Bola, A. S., Andjock, Y. C. N., Choffor, E. N., Nanci, E., Esene, I. N., & Djomou, F. (2021). Bilateral sphenoid sinus mucocele observed in Yaounde-Cameroon: A case report. *Pan African Medical Journal*, 39, Article 198.
- [29] Kim, Y. W., Yi, K. I., Kang, M. J., Kim, S. D., Mun, S. J., & Cho, K. S. (2021). The clinical and radiologic features affecting the ocular symptoms in patients with paranasal sinus mucocoeles involving the orbit. *Journal of Craniofacial Surgery*, 32(3), e247–e251. <https://doi.org/10.1097/SCS.0000000000006982>
- [30] Li, J., Luo, R., & Gao, W. (2025). Diagnostic value of nasal sinus computed tomography/magnetic resonance imaging examination and serum cytokines in unilateral benign sphenoid sinus lesions. *Journal of Radiation Research and Applied Sciences*, 18(1), 101187. <https://doi.org/10.1016/j.jrras.2024.101187>
- [31] Nardi, C., Maraghelli, D., Pietragalla, M., Scola, E., Locatello, L. G., Maggiore, G., ... Bartolucci, M. (2022). A practical overview of CT and MRI features of developmental, inflammatory, and neoplastic lesions of the sphenoid body and clivus. *Neuroradiology*, 64(8), 1483–1509. <https://doi.org/10.1007/s00234-022-02986-x>
- [32] Liu, H. Y., Bai, Z. Y., Jing, W., Yang, X. F., Kwon, T. G., Yun, K. M., ... Bing, L. (2023). Application of sphenoid sinus morphological characteristics in sex estimation based on magnetic resonance imaging images. *International Journal of Morphology*, 41(4). <https://doi.org/10.4067/S0717-95022023000401166>
- [33] Adewole, V., Boubaker, F., Hossu, G., Nguyen, D. T., Blum, A., Gondim Teixeira, P. A., ... Gillet, R. (2025). Diffusion-weighted MRI over standard MRI for differential diagnosis between mucopyocele and mucocoeles. *The Laryngoscope*, 135(3), 1008–1014. <https://doi.org/10.1002/lary.31833>